



Contents lists available at ScienceDirect

# Vaccine

journal homepage: [www.elsevier.com/locate/vaccine](http://www.elsevier.com/locate/vaccine)

## Comparison of the local safety of two multi-component feline vaccines, adjuvanted (1 mL) versus non-adjuvanted at reduced volume (0.5 mL), using computed tomography imaging

Verena Haist<sup>a,\*</sup>, Fanny Bellebeau-Barbier<sup>b</sup>, Camille Montange<sup>b</sup>, Laurent Lemaitre<sup>b</sup>, Aissatou Diawara<sup>b</sup>, Anne-Laure Guiot<sup>c</sup>, Alexandra Nicolier<sup>d</sup>, Emilie Latronico<sup>e</sup>, Emmanuel Chereul<sup>e</sup>, Sylvie Brunet<sup>f</sup>, Jean-Philippe Tronel<sup>f</sup>

<sup>a</sup> Boehringer Ingelheim Vetmedica GmbH, Binger Strasse 173, 55216 Ingelheim am Rhein, Germany

<sup>b</sup> Boehringer Ingelheim Animal Health France, Centre de Recherche de Saint-Vulbas, 805 Allée des Cyprès, 01150 Saint-Vulbas, France

<sup>c</sup> CPB, 2 Place des Quatre Vierges, 69110 Sainte Foy les Lyon, France

<sup>d</sup> Laboratoire VetDiagnostics, 3 Avenue de la Victoire, 69260 Charbonnières-les-Bains, France

<sup>e</sup> Voxcan, 1305 Route de Lozanne, 69380 Dommartin, France

<sup>f</sup> Boehringer Ingelheim Animal Health France, 29 Avenue Tony Garnier, 69007 Lyon, France

### ARTICLE INFO

#### Article history:

Received 21 March 2023

Received in revised form 7 June 2023

Accepted 12 June 2023

Available online 23 June 2023

#### Keywords:

Local safety

Feline vaccine

Reduced volume

Adjuvanted

Computed tomography

Inflammation

### ABSTRACT

In 2020, a new 0.5 mL presentation of PUREVAX<sup>®</sup> RCP FeLV was registered and introduced in Europe.

The objectives of this study were to investigate the local safety of this non-adjuvanted vaccine at reduced volume by classical methods (clinical examination, histopathology) and to evaluate the suitability of an alternative non-invasive methodology, the computed tomography (CT). For this purpose, the course of local reactions was assessed for 3 months after subcutaneous injection of PUREVAX<sup>®</sup> RCP FeLV 0.5 mL and compared to an adjuvanted vaccine, LEUCOFELIGEN<sup>®</sup> FeLV/RCP 1.0 mL.

Injection site reactions consisted mainly of swelling reactions, which were more frequent, more pronounced and long-lasting in the adjuvanted vaccine group. Microscopically, in this group, moderate to severe inflammatory reactions were observed on day 7 (D7) and D21 post-injection and still present on D84, while mild inflammatory lesions were observed in the non-adjuvanted vaccine group only on D7 and D21. With the adjuvanted vaccine, inflamed areas were measurable by CT scan in all cats on D7 and D21, whereas they were detected only on D7 and only in 20 % of cats from the non-adjuvanted vaccine group. Besides the higher frequency, the mean inflamed volume was nearly 300 times larger in adjuvanted vaccine group on D7.

Using different methodologies, the favorable safety profile of PUREVAX<sup>®</sup> RCP FeLV 0.5 mL was confirmed. Furthermore, the vaccine is aligned with current vaccination guidelines by inducing less inflammatory reactions, being adjuvant-free and injectable under a reduced volume, thus improving the convenience of administration in recommended sites (eg, legs).

CT scan proved to be a suitable non-invasive method for the experimental follow-up of injection site reactions, yielding results consistent with clinical assessment and histopathology on D7 and D21. CT scan substantiated large differences between the investigated vaccines with a more prominent inflammatory reaction after injection of an adjuvanted vaccine.

© 2023 The Authors. Published by Elsevier Ltd. This is an open access article under the CC BY-NC-ND license (<http://creativecommons.org/licenses/by-nc-nd/4.0/>).

**Abbreviations:** CT, computed tomography; D, day; FCV, feline calicivirus; FeLV, feline leukemia virus; FHV-1, feline herpesvirus-1; FPV, feline parvovirus; FISS, feline injection site sarcoma; ISS, injection site score.

\* Corresponding author.

**E-mail addresses:** [verena.haist@boehringer-ingelheim.com](mailto:verena.haist@boehringer-ingelheim.com) (V. Haist), [fanny.bellebeau-barbier@boehringer-ingelheim.com](mailto:fanny.bellebeau-barbier@boehringer-ingelheim.com) (F. Bellebeau-Barbier), [camille.montange@boehringer-ingelheim.com](mailto:camille.montange@boehringer-ingelheim.com) (C. Montange), [laurent.lemaitre@boehringer-ingelheim.com](mailto:laurent.lemaitre@boehringer-ingelheim.com) (L. Lemaitre), [aissatou.diawara@boehringer-ingelheim.com](mailto:aissatou.diawara@boehringer-ingelheim.com) (A. Diawara), [a-l.guiot@cegetel.net](mailto:a-l.guiot@cegetel.net) (A.-L. Guiot), [a.nicolier@vetdiagnostics.fr](mailto:a.nicolier@vetdiagnostics.fr) (A. Nicolier), [emilie.latronico@hotmail.fr](mailto:emilie.latronico@hotmail.fr) (E. Latronico), [emmanuel.chereul@voxcan.fr](mailto:emmanuel.chereul@voxcan.fr) (E. Chereul), [sylvie.brunet@boehringer-ingelheim.com](mailto:sylvie.brunet@boehringer-ingelheim.com) (S. Brunet), [jean\\_philippe.tronel@boehringer-ingelheim.com](mailto:jean_philippe.tronel@boehringer-ingelheim.com) (J.-P. Tronel).

<https://doi.org/10.1016/j.vaccine.2023.06.045>

0264-410X/© 2023 The Authors. Published by Elsevier Ltd.

This is an open access article under the CC BY-NC-ND license (<http://creativecommons.org/licenses/by-nc-nd/4.0/>).

## 1. Introduction

Vaccination is essential for the prevention of many infectious diseases in cats and recommendations have been made in World Small Animal Veterinary Association (WSAVA) [1], American Animal Hospital Association/American Association of Feline Practitioners (AAHA/AAFP) [2], and European Advisory Board on Cat Diseases (ABCD) feline vaccination guidelines [3,4]. Cats are usually vaccinated against the major feline viral pathogens, such as feline parvovirus (FPV), feline calicivirus (FCV), feline herpesvirus-1 (FHV-1), and particularly kittens and young adults often receive vaccines against feline leukemia virus (FeLV).

Adverse reactions after vaccine injection are considered rare [5]. In a large survey conducted in the United States between 2002 and 2005 involving nearly 500,000 cats, 52 adverse reactions (of any kind, including very minor reactions) per 10,000 cats were reported within 30 days of vaccination [6]. The most serious adverse reactions are feline injection site sarcomas (FISS), which are malignant tumors of mesenchymal origin developing at sites of previous vaccination or injection. FISS are highly locally invasive, fast growing, may metastasize to remote sites, and require aggressive and radical surgical resection, due to a high rate of local tumor recurrence [7–9]. Current estimates of the incidence are low and vary by country, depending on which vaccines are used (types and pathogens) and population susceptibility [2]. Reported prevalence of FISS was 1 FISS per 5000–12,500 vaccination visits in the United Kingdom [10], 0.63 FISS per 10,000 vaccinated cats in the United States and Canada [11], and 16 out of 10,000 cats for a general veterinary practice in Poland [12].

The pathogenesis of FISS is still unclear and etiology likely multifactorial, but the most widely accepted hypothesis is that, in predisposed cats, a chronic inflammatory reaction at the injection site is the triggering factor for malignant transformation of mesenchymal cells [1,7–9,13–15]. Adjuvanted vaccines were shown to induce a more intense local inflammation than non-adjuvanted ones [14,16]. Some epidemiological studies report an association between the administration of inactivated adjuvanted vaccines and subsequent development of FISS [17–20], others did not [21,22]. To address the risk of FISS, current feline vaccination guidelines recommend vaccinating in the lower distal limb or lateral abdominal skin (to facilitate amputation/excision in the event of FISS), avoiding over-vaccination, and monitoring vaccination sites using the 3–2–1 rule [1,2,9,23]. This rule advises to biopsy any mass at a vaccination site if the mass is still present 3 months after vaccination, is growing >2 cm in diameter, or is increasing in size 1 month after vaccination [9]. In addition, the WSAVA and the ABCD guidelines recommend the use of non-adjuvanted vaccines, whenever possible, and reducing local inflammation by avoiding the administration of any irritating substance [1,9,23].

PUREVAX<sup>®</sup> is a fully adjuvant-free feline vaccine range, which received marketing authorization in Europe in 2005. The multi-component concept allows the combination of various lyophilized vaccines (against FHV-1, FCV, FPV, or *Chlamydia felis*) (“RCPCh”) with a liquid vaccine component (against FeLV or rabies) or a diluent at a final volume of 1 mL. A kinetic study of histopathological changes in the subcutis of cats after vaccine injection showed that PUREVAX<sup>®</sup> RCPCh FeLV induced significantly less severe and less sustained local tissue inflammation than adjuvanted vaccines [16]. In order to provide a faster injection experience for the cats as well as improve the easiness of administration of the vaccine in alternative sites with less loose skin, a new presentation of PUREVAX<sup>®</sup> RCPCh FeLV with unchanged antigen content but a reduced volume (0.5 mL) was developed. A laboratory study and a randomized controlled field trial showed that the 0.5 mL presentation of PUREVAX<sup>®</sup> RCPCh FeLV was well tolerated, induced even

less injection site reactions than the 1 mL dose and remained as immunogenic [24].

In 2020, the 0.5 mL presentation was centrally registered by the European Medicines Agency and launched in Europe. The objectives of this study were to investigate the local safety of this new presentation of a non-adjuvanted vaccine at reduced volume by classical methods (clinical examination, histopathology), using an adjuvanted vaccine as benchmark, and to introduce computed tomography (CT) as an alternative non-invasive methodology for injection site monitoring. For this purpose, the course of local reactions after the subcutaneous injection of PUREVAX<sup>®</sup> RCP FeLV 0.5 mL was assessed for 3 months and compared to an adjuvanted vaccine, LEUCOFELIGEN<sup>®</sup> FeLV/RCP 1.0 mL in young adult cats.

## 2. Material and methods

### 2.1. Vaccines

PUREVAX<sup>®</sup> RCP FeLV (Boehringer Ingelheim, France) is a multi-component non-adjuvanted vaccine composed of a lyophilizate containing two inactivated calicivirus strains (FCV 431, FCV G1), and modified live feline rhinotracheitis (FHV F2) and panleukopenia (FPV PLI IV) viruses (PUREVAX<sup>®</sup> RCP, Boehringer Ingelheim, France), reconstituted with 0.5 mL of a liquid recombinant canarypox-FeLV vaccine (PUREVAX<sup>®</sup> FeLV, Boehringer Ingelheim, France).

LEUCOFELIGEN<sup>®</sup> FeLV/RCP (Virbac, France) is a multi-component vaccine composed of a lyophilizate containing modified live attenuated feline calicivirus (FCV F9), feline rhinotracheitis virus (FHV F2), and panleukopenia virus (FPV LR 72), reconstituted with 1 mL of a liquid FeLV subunit vaccine adjuvanted with aluminum hydroxide and *Quillaja saponaria* (AlOH/Quil A).

A sterile saline solution (0.9% NaCl) (Osalia, France) was used as negative control for each vaccine.

### 2.2. Animals

Fifteen female and 15 male specific pathogen free cats (Hill Grove strain, Centre Lago, France) were used in this study. On average, they were aged 1 year (range: 10–32 months) and weighed 4 kg (range: 2.6–6.2 kg) at inclusion. Cats were randomly assigned according to their sex and weight to two treatment groups of 15 cats each. Randomization included the time point of biopsy collection. Females and males were housed in two separated rooms, and treatment groups intermingled in each room.

### 2.3. Study design

Before vaccination, the injection sites were shaved with an electric clipper, then at regular intervals during the study, and a marker pen was used to precisely delineate the injection site.

On day 0 (D0), all cats received one of the vaccines into the right hindlimb and saline solution into the left hindlimb. Injections were administered subcutaneously in the proximal lateral part of the hindlimb, caudal to the femoral bone, using a 26G needle. Cats from group 1 (8 males, 7 females) received LEUCOFELIGEN<sup>®</sup> FeLV/RCP and 1 mL saline, cats from group 2 (7 males, 8 females) received PUREVAX<sup>®</sup> RCP FeLV and 0.5 mL saline. Group 1 was referenced as adjuvanted vaccine group, and group 2 as non-adjuvanted vaccine group.

The schedule of clinical monitoring, CT scans, and biopsies for histopathological examinations is summarized in Fig. 1. In addition, body weights were measured weekly. For vaccine administra-

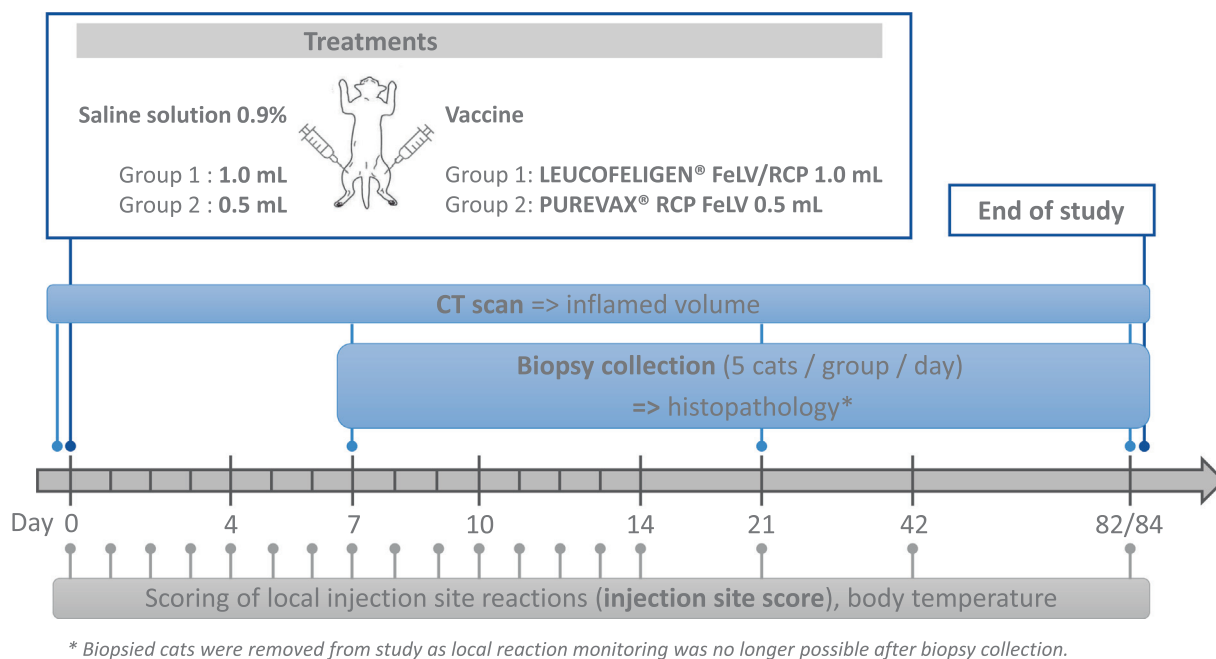


Fig. 1. Study design (main parameters).

tion, CT acquisitions and biopsies, cats were anesthetized using a mixture of isoflurane and oxygen.

Tissue samples of injection sites were collected from 5 cats of each group on D7, D21 and D82/D84 (2 different dates due to logistical constraints). After biopsy collection, cats were removed from the study and clinical follow-up was performed until complete recovery from surgery. Thus, CT scans were performed for all 30 cats on D0 and D7, 20 cats on D21 (10 per group), and 10 cats on D82/84 (5 per group).

The in-life phase and CT scans were performed at Voxcan (Dommartin, France). Histopathological analyses were done at VetDiagnostics (Charbonnières-les-Bains, France). This study was carried out in accordance with the EU Directive 2010/63/EU for animal experiments and the National Research Council’s Guide for the Care and Use of Laboratory Animals. The study was approved by the Voxcan ethical committee and the French authorities (Ministry of Higher Education, Research and Innovation, approval number APAFIS #33905-2021111211107009 v5).

2.4. Clinical monitoring

All cats were observed for about 15 min after vaccine injection for any immediate adverse event, and then daily for general health throughout the study. Body temperature was recorded daily for 14 days following vaccination in awake cats via a thermo-chip (Allflex®, France), which was subcutaneously implanted in the interscapular region. Body weight was measured weekly throughout the study.

Table 1 Scoring scheme for injection site reactions.

Score	Swelling	Redness	Pain	Pruritus
0	Absent	Absent	Absent	Absent
1	Mild* (5–10 mm)	Mild (5–10 mm)	Mild (no reaction when touched, mild sensitive reaction only with palpation)	Present (cat scratches itself during examination)
2	Moderate* (11–15 mm)	Moderate (11–15 mm)	Moderate (marked sensitive reaction with palpation and/or mild sensitive reaction with touching)	–
3	Severe* (≥16 mm)	Severe (≥16 mm)	–	–

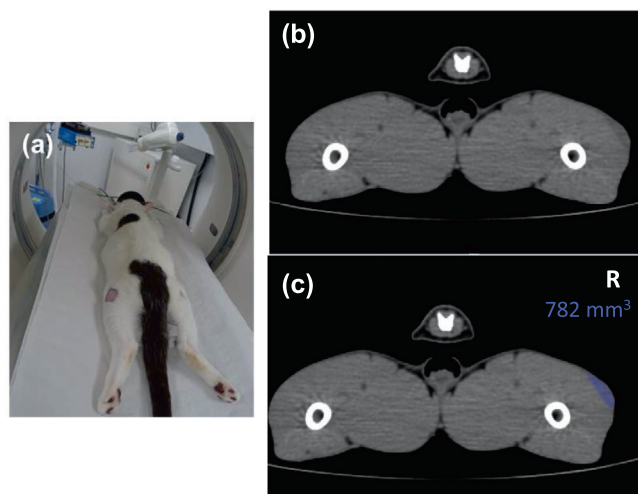
\* If swelling was present, the type of swelling was recorded as “soft” (edema-like) or “firm” (nodule-like).

Clinical assessment of injection sites was performed daily for at least 14 days after injection in all cats; and if reactions were still persisting thereafter, daily assessment was continued until 3 days after complete resolution. Injection sites were also examined in all cats on D42 and D82/D84. The scoring scheme for the injection site reactions (swelling, redness, pain and pruritus) is presented in Table 1. When injection site reactions were examined on anesthetized cats, pain and pruritus could not be assessed.

2.5. CT scan

CT acquisitions were performed before vaccination on D0, then on D7, D21 and D82/D84 covering the regions of interest (lateral aspects of the hindlimbs) using a GE Brightspeed 16 CT Scanner (General Electric Healthcare, United Kingdom). For CT acquisition, the cats were positioned in ventral recumbency (Fig. 2). An effort was made to avoid any pressure on the skin for all injection sites. One acquisition was done per cat and time point with no contrast agent.

Scanning parameters were axial resolution of 187 μm, slice thickness of 310 μm after reconstruction, acceleration voltage of 120 kV, intensity of 150 mA, gantry rotation time of 800 ms and beam pitch of 0.938 or 0.562. Image reconstruction was performed using the STANDARD algorithm. CT acquisitions and image analyses were performed using the software Avizo 2021.1, by manual segmentation. On several adjacent consecutive image slices, a manual image segmentation process was used to identify the voxels corresponding to the subcutaneous inflamed area with



**Fig. 2.** Cat during CT scanning and examples of CT images (transverse sections of hind limbs). (a) For CT acquisition, the cats were positioned in ventral recumbency. (b) and (c) the inflamed area (subcutaneous area in different grayscale lateral on right hind limb) was determined by manual delineation in adjacent consecutive image slices (blue coloration in (c) for better visualization), then the volume was calculated via an interpolation procedure. (For interpretation of the references to colour in this figure legend, the reader is referred to the web version of this article.)

associated darker gray borders. The volume of the inflamed zone (in mm<sup>3</sup>) was obtained via an interpolation procedure. When no inflamed area was visible, no segmentation was performed.

Examples of CT imaging and evaluation are shown in Fig. 2.

### 2.6. Biopsies and histopathologic examinations

Punch biopsies were taken from the vaccine and saline injection sites of 5 cats per group on D7, D21, and D82/D84. One tissue sample containing skin, subcutaneous tissue, sometimes muscle was collected at the center of each injection site using a sterile biopsy punch (8 mm diameter) and fixed in 4 % formaldehyde solution. For processing, each biopsy was longitudinally cut in halves and both halves embedded in paraffin. From each paraffin block, one hematoxylin-eosin-stained slide was prepared and analyzed using a light microscope by a board-certified pathologist. A morphological diagnosis was provided for each biopsy.

### 2.7. Statistical analyses

A daily injection site score (ISS) was calculated by adding the clinical scores of swelling, redness, pain and pruritus reactions per cat and per day. Additionally, weekly total ISSs per cat were calculated for the study periods D1–D7, D8–D14, and D15–D21 by adding the individual daily ISSs for the given period. For each period, the total ISSs were compared between groups using the Wilcoxon-Mann-Whitney’s test (exact).

The volume of inflamed areas measured by CT scan were compared between groups at each time point (D7, D21, and D82/D84) using a *t*-test.

All analyses were conducted using the SAS software (SAS Institute, Cary, NC; version 9.4).

## 3. Results

### 3.1. Clinical examination

#### 3.1.1. Systemic reactions

All cats remained healthy, and no systemic adverse events related to vaccine injection were reported.

There was an overall weight gain of all cats during the course of the study. Single cats showed a mild transient weight loss between the baseline weighing (D-7/D-4) and D7, which was probably caused by the various study procedures involving general anesthesia at study start. No hyperthermia ( $\geq 39.5$  °C) was recorded within 2 weeks after vaccine injection in any group (data not shown).

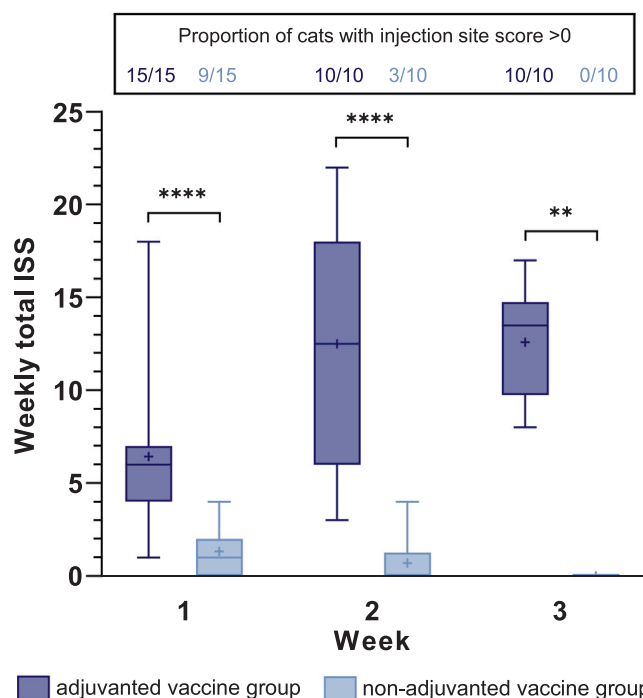
#### 3.1.2. Injection site reactions

No reactions were observed at the sites injected with saline in both groups, except for 1 cat in the non-adjuvanted vaccine group which was recorded with a mild swelling on D6.

Within 6 days after injection of the adjuvanted vaccine, all cats (N = 15) developed mild to severe swelling reactions, which were visible for 2–32 days. All cats (N = 10) from this group still presented swelling reactions on D21, and in the 5 cats remaining on study after D21, swelling lasted until D30 (1 cat), D33 (3 cats), and D40 (1 cat). Most swellings had a firm consistency and were more intense during the second and third week after vaccine injection. In addition, 5 cats from the adjuvanted vaccine group experienced mild to severe redness for 3–6 days.

After injection of the non-adjuvanted vaccine, nine out of 15 cats had transient swelling reactions, which were visible for 1–4 days and were of mild intensity, except for 2 cats (1 cat experienced moderate swelling for 2 days, and 1 cat experienced severe swelling for 1 day). Most swellings had a soft consistency. In the non-adjuvanted vaccine group, no swellings were observed after D7, except for 1 cat on D11 and 2 cats on both D12 and D13. One cat experienced mild redness on a single day (D3).

Neither pain nor pruritus was observed in any group. Weekly total ISSs were significantly higher in the adjuvanted vaccine group than in the non-adjuvanted vaccine group during the D1–D7 period (median [range]: 6.0 [1–18] versus 1.0 [0–4]) ( $p < 0.0001$ ), the D8–D14 period (median [range]: 12.5 [3–22] versus 0 [0–4]) ( $p < 0.0001$ ), and the D15–D21 period (median [range]: 13.5 [8–17] versus 0 [0–0]) ( $p < 0.01$ ) (Fig. 3).



**Fig. 3.** Weekly total injection site scores per group. Weekly total ISS, clinically assessed at the vaccine injection site for week 1 (D1–D7), week 2 (D8–D14), and week 3 (D15–D21) after injection, and proportion of cats with an ISS > 0 per period and group (\*\*  $p < 0.01$ , \*\*\*\*  $p < 0.0001$ , Wilcoxon-Mann-Whitney’s test).



**Fig. 4.** Hindlimb of a cat 21 days after the injection of the adjuvanted vaccine. A moderate swelling reaction (score 2) was still present at the injection site 3 weeks after administration of the adjuvanted vaccine.

An example of a swelling reaction persisting 21 days after injection of the adjuvanted vaccine is shown in Fig. 4.

### 3.2. CT scan

Before treatment, there were no discernible subcutaneous alterations at any of the designated injection sites, and all saline injected sites remained unaltered in all cats until the end of the study.

One week after injection of the adjuvanted vaccine, inflamed areas were detected at the vaccination sites of all cats (15/15, 100 %) with a mean volume of 2286.5 mm<sup>3</sup> (range: 182–5211 mm<sup>3</sup>). In contrast, inflamed areas were only visible in 3 cats (3/15, 20 %) injected with the non-adjuvanted vaccine (9.2, 34.6, and 75.7 mm<sup>3</sup>, respectively), resulting in a mean volume of 8 mm<sup>3</sup> for this group.

Three weeks post vaccine injection, inflammation was still present in all cats (10/10, 100 %) from the adjuvanted vaccine group, with a mean inflamed volume of 1054 mm<sup>3</sup> (range: 265–3179 mm<sup>3</sup>), whereas no inflamed areas were visible in cats from the non-adjuvanted vaccine group (Fig. 5).

Twelve weeks post vaccination, no subcutaneous inflammation was detected by CT scan in any vaccine injection site of the remaining cats from both groups.

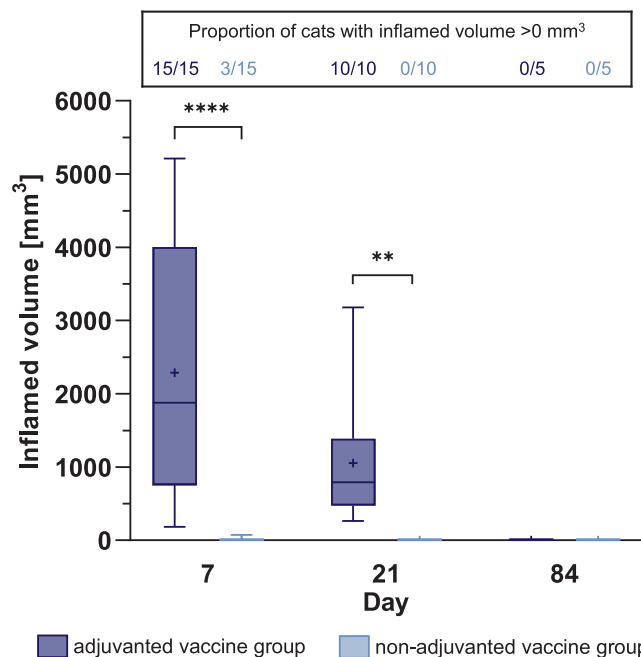
The inflamed volumes measured by CT scan were significantly higher in the adjuvanted vaccine group than in the non-adjuvanted vaccine group on D7 ( $p < 0.0001$ ) and D21 ( $p < 0.01$ ).

Representative CT scan images from both groups are shown in Fig. 6.

Overall, CT scan results are consistent with ISSs recorded on the respective days of CT acquisition (D7 and D21) in terms of frequency, duration, and magnitude. Almost all cats from the adjuvanted vaccine group presented with injection site reactions, i.e. ISS > 0 (14/15 on D7, 10/10 on D21) and a higher ISS (mean [range]: 1.4 [0–3] on D7, and 2.0 [1–3] on D21) whereas few cats from the non-adjuvanted vaccine group had local reactions (2/15 on D7, 0/10 on D21) with a low ISS (mean [range]: 0.1 [0–1] on D7, and 0 on D21).

### 3.3. Histopathological findings

No lesions were observed at any saline injection site at the different time points. At the vaccine-injected sites, microscopic alter-



**Fig. 5.** Inflamed volume at injection site – CT scan. Inflamed volumes assessed by CT scan at the vaccine injection site on D7, D21 and D84 and proportion of cats with a detectable inflamed area per examination day and group (\*\*  $p < 0.01$ , \*\*\*\*  $p < 0.0001$ ,  $t$ -test).

ations were present in all examined cats from both groups on D7 and on D21, while on D82/84, lesions were detected in all cats from the adjuvanted group and only in 1 cat from the non-adjuvanted group. Type and severity of microscopic changes were clearly different between the groups.

#### 3.3.1. One week post vaccine injection (D7)

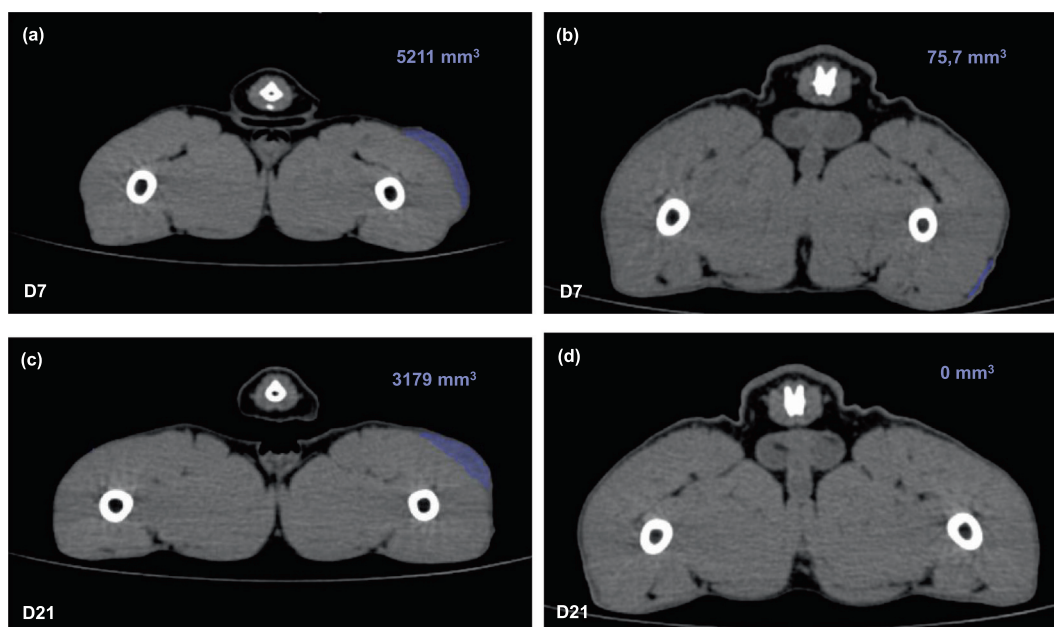
With the adjuvanted vaccine, all 5 injection sites exhibited moderate to severe areas of necrosis in the subcutaneous adipose tissue (extending into subcutaneous muscle in 1 cat) associated with fibrin deposition, edema and hemorrhages, surrounded by numerous viable and degenerated neutrophils admixed with lymphocytes, plasma cells and macrophages. Granular basophilic material was present in the cytoplasm of macrophages and extracellular in the necrotic center of the lesions in all samples.

In the non-adjuvanted vaccine group, minimal to moderate perivascular infiltrates of lymphocytes, plasma cells and macrophages were present in the subcutaneous adipose tissue (and subcutaneous muscle in 1 cat) in all samples, associated with vascular congestion and edema.

#### 3.3.2. Three weeks post vaccine injection (D21)

All 5 injection sites with the adjuvanted vaccine exhibited severe nodular to coalescing accumulations of macrophages, multinucleate giant cells, neutrophils, lymphocytes and plasma cells in the subcutaneous adipose tissue (extending into subcutaneous muscle in 1 cat), which were frequently centered around areas of necrosis and fibrin deposition. Granular basophilic material was present in the cytoplasm of macrophages and extracellular in the necrotic center of the lesions in all samples.

All sites injected with the non-adjuvanted vaccine showed minimal to moderate perivascular infiltrates in the subcutaneous adipose tissue (and subcutaneous muscle in 2 cats). Infiltrates consisted of lymphocytes, plasma cells and macrophages, some-



**Fig. 6.** Representative CT scan images on D7 and D21. CT scan images illustrating the development of an inflamed zone on D7 and D21 from a cat injected with the adjuvanted vaccine [(a) and (c)] and from a cat injected with the non-adjuvanted vaccine [(b) and (d)].

times forming lymphoid nodules, and were associated with fibroblast hypertrophy and collagen deposition.

### 3.3.3. Twelve weeks post vaccine injection (D82/D84)

In the adjuvanted vaccine group, 3 cats showed minimal to moderate multifocal accumulations of macrophages, lymphocytes and plasma cells in the subcutaneous adipose tissue, with cytoplasmic granular basophilic material in macrophages. One cat exhibited minimal perivascular infiltrates of the same composition including the granular material. One cat presented only single macrophages in the subcutis with cytoplasmic granular basophilic material.

With the non-adjuvanted vaccine, only one cat showed microscopic alterations consisting in a focal perivascular cuff of lymphocytes and plasma cells in the subcutis.

Histopathological diagnoses are summarized per group in Table 2, and representative microscopic images from D7, D21 and D84 are shown in Fig. 7.

## 4. Discussion

The main objective of this laboratory study was to investigate the local safety of the non-adjuvanted vaccine PUREVAX<sup>®</sup> RCP FeLV 0.5 mL and compare it to an adjuvanted vaccine (LEUCOFELIGEN<sup>®</sup> FeLV/RCP) 1.0 mL for 3 months after subcutaneous administration in young adult cats. Another objective was to evaluate the suitability of CT scan as a non-invasive method for assessing subcutaneous inflammatory reactions and if the results were comparable to clinical examinations and consistent with histopathology.

Two advanced diagnostic imaging techniques, CT scan and Magnetic resonance imaging (MRI), were considered for the monitoring of injection site reactions. MRI was successfully used in pigs and sheep for the assessment of local reactions after vaccination [25–27]. CT scan was reported as a useful tool to detect subcutaneous aluminum hydroxide-induced granulomas in sheep [28]. CT scan or MRI is recommended to assess the tumor size of feline fibrosarcoma and determine the extent of invasion, plan adequate surgical margins, and the area that needs to be included in the radiation treatment field [7,29,30]. Contrast-enhanced CT

scans were shown more accurate for determining FISS tumor volume than physical examination estimates and caliper measurements, and CT measurements tended to be larger than clinical dimensions [7,31]. We conducted a pilot study comparing CT scan and MRI after injection of a multi-component adjuvanted vaccine to cats. MRI images had a higher contrast than CT images; however, the inflamed tissue presented heterogeneous and sometimes with an unequivocal hypersignal (from fluid) extending into the superficial skin. In contrast, CT images appeared homogenous with a good visualization of the borders of the inflamed tissue (Supplementary Fig. 1). Moreover, the resolution of the CT scan was 13 times higher than the MRI. As a result, segmentation and volume quantification operations were more reproducible using the CT imaging, which was selected for the assessment of injection site reactions in the present study. In addition, CT scan methodology is more convenient than MRI in terms of costs, availability, time, and animal welfare (quicker examination, possible use of short volatile anesthesia).

The suitability and accuracy of the CT imaging was evaluated comparing a non-adjuvanted vaccine and a vaccine adjuvanted with AIOH/Quil A, as a difference in the type of induced local reactions could be expected. All cats served as their own internal control by receiving a contralateral injection of 0.5 mL or 1 mL saline solution, according to the volume of the injected vaccine. CT imaging was also compared to clinical examination of injection sites and histopathological evaluation, which are classically used to assess the local safety of vaccines.

Different time points were selected for CT imaging and histopathological analyses to compare injection site reactions early after vaccination (D7), at an intermediate period (D21), and during the late-stage healing phase of the reaction (D82/D84). D7 was the best compromise to study the maximum injection site reaction, based on the mentioned pilot study, where the largest inflamed volumes were measured by CT scan between D7 and D14. D21 was selected to assess the level of a persisting inflammatory reaction at the time of a potential second vaccine injection in a primary vaccination scheme. D82/D84, approximately 3 months after vaccination, is also the last time point as per the 3/2/1 rule for the monitoring of the injection site after vaccination.

**Table 2**  
Summary of histopathological findings in punch biopsies from injection sites.

Time of biopsy collection	Injection sites with adjuvanted vaccine (Group 1, LEUCOFELIGEN)	Injection sites with non-adjuvanted vaccine (Group 2, PUREVAX)	Control sites with saline solution (Groups 1 and 2 combined)
D7	5/5: ++ or +++ subacute diffuse fibrino-necrotizing panniculitis with intrahistiocytic and extracellular basophilic granular material 1/5: additional myositis	5/5: (+) or ++ subacute multifocal perivascular mononuclear panniculitis 1/5: additional minimal myositis	10/10: no findings
D21	5/5: ++ or +++ chronic diffuse pyo-/granulomatous panniculitis with intrahistiocytic and extracellular basophilic granular material 1/5: additional myositis	5/5: (+), + or ++ chronic multifocal perivascular mononuclear panniculitis 1/5: additional myositis	10/10: no findings
D82/84	3/5: (+), + or ++ chronic multifocal granulomatous panniculitis with intrahistiocytic basophilic granular material 1/5: + chronic perivascular mononuclear panniculitis with rare macrophages with intracytoplasmic basophilic granular material 1/5: Rare macrophages with intracytoplasmic basophilic granular material	1/5: (+) chronic multifocal perivascular mononuclear panniculitis 4/5: no findings	10/10: no findings

n/N: proportion of animals with this finding.  
(+) minimal, + mild, ++ moderate, +++ severe.

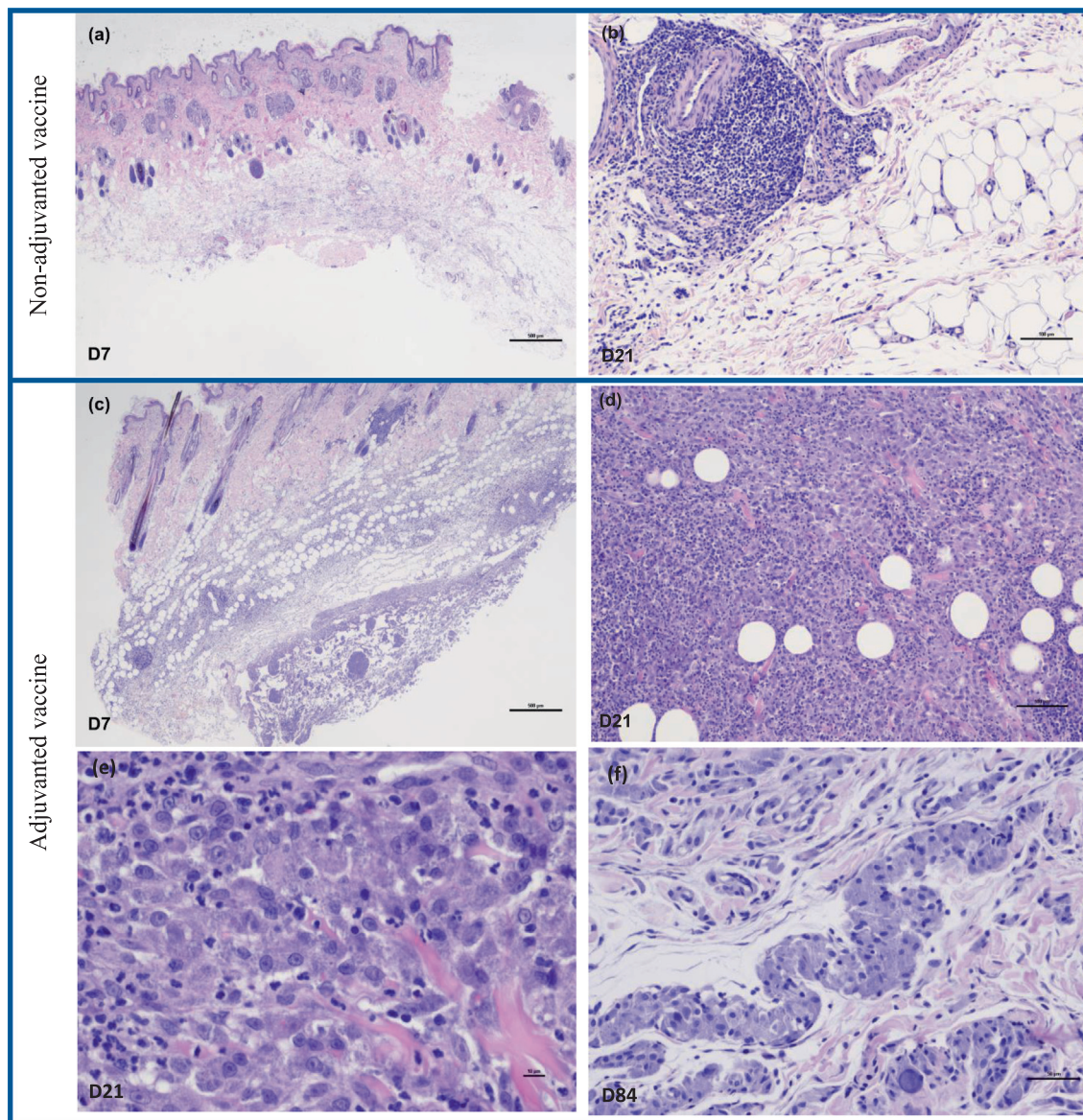
Both vaccines were well tolerated in terms of systemic reactions, with no vaccine-related effects on the general condition or on the body weight, and no hyperthermia. Local reactions were clearly different between vaccines in terms of frequency, intensity, and duration. As the two vaccines differ in several characteristics (adjuvanted/non-adjuvanted, antigen strains, type of FeLV vaccine component, volume), the results only apply to the comparison of these two commercially available vaccines. Injection site reactions consisted mainly of swelling. In the adjuvanted vaccine group, swellings were more frequent, intense and long-lasting (all 15 cats affected, still present in all cats on D21, lasting until D40 in 1 cat) than in the non-adjuvanted group, where swelling reactions were mainly of mild intensity, and transient (only 9/15 cats affected in the first week, only 3 cats affected after D7 with the last observation of swelling on D13). Most swelling reactions were of firm consistency after injection of the adjuvanted vaccine, while they were soft after injection of the non-adjuvanted vaccine. Swelling was associated with redness in 33 % of cats receiving the adjuvanted vaccine. Neither pain nor pruritus was reported in any group. Differences between groups were illustrated by the weekly total injection site score, which was significantly higher during the first, second and third week after vaccine injection in the adjuvanted vaccine group. In a previous experimental study, injection site

reactions were also limited to transient swelling reactions after administration of PUREVAX® RCPCh FeLV 0.5 mL in the interscapular region [24].

Examination of the biopsies showed that microscopic alterations were observed in all biopsies from vaccine injected sites, but not in saline injected control sites. In both groups, early inflammatory reactions were present, but they differed clearly in their pattern and were more transient in the non-adjuvanted vaccine group. In the adjuvanted vaccine group, lesions basically consisted of (pyo)granulomatous panniculitis in various phases, presenting with an acute fibrino-necrotizing component at 1 week after vaccination and a more organized chronic appearance at 12 weeks. All vaccination sites in this group contained intralesional basophilic granular material within the cytoplasm of macrophages as well as extracellularly. The lesion intensity was moderate to severe 1 and 3 weeks post-injection, and inflammation was still present – though with slightly decreased intensity – in all 5 cats 12 weeks post-injection. This pattern of microscopic lesions is compatible with the inflammatory reaction provoked by the presence of poorly degradable material in the tissue (“foreign body reaction”) such as alum or mineral oil components of vaccine adjuvants. In vaccination site samples from the non-adjuvanted vaccine group, only minimal to moderate perivascular mononuclear panniculitis was found at 1 and 3 weeks post injection, sometimes with the formation of lymphoid nodules. Twelve weeks post-injection, only 1 out of 5 samples from the non-adjuvanted vaccine group still showed minimal mononuclear inflammation. Similar histopathological changes were described by Day et al. [16] 7, 21 and 62 days after the subcutaneous injection of vaccines containing a lipid-based or AIOH/Quil A as adjuvants, and of a non-adjuvanted vaccine. Similar to the results of this study, a significantly less severe and less sustained local tissue inflammation and a more effective tissue repair were reported with the non-adjuvanted vaccine versus both adjuvanted vaccines [16].

CT scan confirmed that inflammatory reactions were detectable only in the vaccine-injected regions, not in the contralateral limbs with the saline injection. In the adjuvanted vaccine group, inflamed areas were measurable in all cats on D7 and D21, whereas in the non-adjuvanted vaccine group they were detected on D7 only in 3 cats (20 %) and not detectable in any cat on D21. Besides the higher frequency of measurable reactions, the mean inflamed volume was nearly 300 times larger in the adjuvanted vaccine group on D7, and the lowest volume ever measured in this group was still more than two-fold higher than the highest measured volume in the non-adjuvanted vaccine group. The difference of mean inflamed areas was statistically significant between groups on D7 and D21. Overall, inflamed volumes measured by CT scans were consistent with the injection site scores in terms of frequency, duration and magnitude on D7 and D21.

CT imaging showed to be a suitable method to assess the local safety of vaccines under laboratory conditions. CT scan is a non-invasive technique, has no impact on lesion development allowing repeated assessments on the same cat, the extent of alterations can be measured, and the method has a good sensitivity, particularly for exudative or proliferative lesions (comparable to manual examination). Thus, CT imaging could be a useful complementary tool for vaccine development, providing a more accurate and objective monitoring of the inflammatory reaction at the injection site than the standard clinical scoring alone. Clinical examination is still required to assess other signs such as pain, redness and pruritus. For scientific purposes, CT scan could be associated with biopsies at the injection sites for histopathology and a detailed morphological characterization of exudative inflammation, (pre-)neoplastic lesions, and immune activation. Collecting tissue samples via biopsies is also a more ethical approach than collecting injection sites at necropsy.



**Fig. 7.** Histopathologic images from biopsies collected on D7, D21, and D84 after vaccine injection. (a, b) Injection site biopsies from the non-adjuvanted vaccine group. On D7, a perivascular to diffuse mononuclear inflammation was observed (a). On D21, scattered mononuclear cell infiltrates and occasional follicular aggregates were present (b). (c–f) Injection site biopsies from the adjuvanted vaccine group. On D7, necrosis, fibrin exudation, massive influx of neutrophils, and foreign amorphous material were observed (c). On D21, exudate started to be organized by macrophages, resulting in granuloma with ongoing necrosis and a demarcation by granulation tissue (d) with the presence of granular material in the cytoplasm of macrophages (e). On D84, chronic multifocal granulomatous panniculitis with basophilic granular material in the cytoplasm of macrophages was observed (f). Hematoxylin eosin stain (a–f); objective magnification 2× (a, c), 10× (b, d), 20× (e), 40× (f).

In this study, the CT scan documented significant differences between two types of vaccines, which were consistent with clinical examination and histopathological findings on D7 and D21. A more frequent, pronounced and long-lasting inflammatory reaction was induced by an adjuvanted vaccine as compared to a non-adjuvanted vaccine. It should be noted that no reaction was detectable by CT scan after saline injection, whatever the volume injected (0.5 or 1 mL). Microscopy corroborated the differences between the vaccines by revealing different inflammation patterns, resembling a foreign body reaction for the adjuvanted vaccine versus the recruitment of immunity-mediating mononuclear cells – which is favorable after vaccination – for the non-adjuvanted vaccine. Notably, the inflammatory pattern was independent from the time after vaccination, ie, alterations at the sites injected with the adjuvanted vaccine had a necrotic to proliferative component at all time points which was not present in any of the injection sites of

the non-adjuvanted vaccine. Moreover, this difference cannot be attributed solely to the higher injection volume of the adjuvanted vaccine because the same high volume of saline did not cause comparable lesions.

The association between chronic inflammation and neoplastic transformation is well known for several disease entities in humans (eg, *Helicobacter pylori* and gastric cancer, asbestos inhalation and mesothelioma/lung cancer, inflammatory bowel diseases and colorectal carcinoma) and in animals (eg, *Spirocerca lupi* and esophageal cancer in dogs) [15,32]. However, the pathomechanistic role of chronic inflammation and adjuvants, especially aluminum-based ones, in the triggering of malignant transformation in some predisposed cats is still unclear. In experimental studies, no development of fibrosarcoma has ever been reported after vaccine injection, possibly related to the low prevalence of fibrosarcoma and long latency period between injection and malignancy.



nant transformation (2 months to 10 years) [7]. Similarly in this study, despite the occurrence of severe post-vaccinal inflammation in certain cats, pre-/neoplastic alterations were not observed within the observation period of 3 months.

Several epidemiological studies investigated the incidence of FISS in correlation with various factors, eg, overall vaccination frequency, the use of particular vaccines, or the introduction of new vaccine formulations [13,17–22]. However, they gave discordant results. Regarding potentially involved cellular mechanisms, granular crystalline foreign material was found in macrophages and multinucleate giant cells within the inflammatory reaction at the injection site [16], and later in the transformed fibroblasts of FISS biopsy samples, which was identified by electron probe X-ray microanalysis as aluminum and oxygen [13,33,34]. In our study, similar granular foreign material, likely components of the vaccine, was still observed in intralésional macrophages 3 months after injection of the adjuvanted vaccine. It has been suggested that the persistence of the inflammatory and immunological reactions associated with the presence of aluminum in the injection sites predisposes the cat to a derangement of its fibrous connective tissue repair response, eventually leading to neoplasia in some of these cases [13]. Different mechanisms by which the inflammatory reaction causes tumor development have been proposed. Overexpression of growth factors and transcriptional factors (NF- $\kappa$ B and STAT3), activation of oncogenes, mutations in the tumor suppressor gene p53 have been found in FISS and may play a role in its pathogenesis [7,9,35,36]. Further studies with extended monitoring of the cats are needed to investigate both, the long-term evolution of severe local reactions and the molecular mechanisms involved.

## 5. Conclusion

Using different methodologies, this study confirmed the favorable safety profile of PUREVAX<sup>®</sup> RCP FeLV 0.5 mL. Local reactions were significantly less frequent, less intense and more transient after administration of this non-adjuvanted vaccine than with an adjuvanted vaccine. The use of this vaccine is well aligned with the current vaccination guidelines, since it is adjuvant-free and induces only mild inflammatory reactions. The reduced volume also allows convenient administration even at distal sites (eg, legs).

CT scan proved to be a suitable non-invasive method for the experimental follow-up of injection site reactions, yielding results consistent with clinical assessment and histopathology on D7 and D21. CT scan substantiated large differences between the vaccine types injected.

## Data availability

Data will be made available on request.

## Declaration of Competing Interest

The authors declare the following financial interests/personal relationships which may be considered as potential competing interests: VH, FBB, CM, AD, LL, SB and JPT are employees of Boehringer Ingelheim Animal Health. EL and EC are employees of Voxcan, whose contribution to the study was funded by Boehringer Ingelheim Animal Health. AN is employee of VetDiagnostics, whose contribution to the study was funded by Boehringer Ingelheim Animal Health. The contribution of ALG to the publication was funded by Boehringer Ingelheim Animal Health. Verena Haist reports a relationship with Boehringer Ingelheim Animal Health that includes: employment. Fanny Bellebeau-Barbier reports a relationship with Boehringer Ingelheim Animal Health that includes: employment.

Camille Montange reports a relationship with Boehringer Ingelheim Animal Health that includes: employment. Aissatou Diawara reports a relationship with Boehringer Ingelheim Animal Health that includes: employment. Laurent Lemaitre reports a relationship with Boehringer Ingelheim Animal Health that includes: employment. Sylvie Brunet reports a relationship with Boehringer Ingelheim Animal Health that includes: employment. Jean-Philippe Tronel reports a relationship with Boehringer Ingelheim Animal Health that includes: employment.

## Acknowledgements

The authors are sincerely grateful to the Voxcan team.

## Funding

The study was fully funded by Boehringer Ingelheim Animal Health France.

## Disclaimer

PUREVAX<sup>®</sup> is a registered trademark of Boehringer Ingelheim Animal Health. Any references in this article to this trademark are informative only and not intended for commercial purposes.

## Authors' contributions and role of the funder/sponsor

The co-authors employed by Boehringer Ingelheim were responsible for the overall study design, the analytical plan and the statistical analysis. VH and FBB designed and scientifically led the study and interpreted all data. SB, JPT and LL developed the study concept and provided technical expertise. CM supported the experimental work. AD conducted the statistical analysis of the study. VH, FBB and JPT helped to draft the manuscript.

EC provided the resources and expertise required for CT imaging and analysis. EL carried out the experimental work (in-life phase) and analyzed data. AN carried out the histopathological evaluation. ALG drafted the manuscript.

All authors read and approved the final manuscript.

## Appendix A. Supplementary material

Supplementary data to this article can be found online at <https://doi.org/10.1016/j.vaccine.2023.06.045>.

## References

- [1] Day MJ, Horzinek MC, Schultz RD, Squires RA. Vaccination Guidelines Group (VGG) of the World Small Animal Veterinary Association (WSAVA). WSAVA Guidelines for the vaccination of dogs and cats. *J Small Anim Pract* 2016;57(1): E1–E45. <https://doi.org/10.1111/isap.2.12431>.
- [2] Stone AE, Brummet GO, Carozza EM, Kass PH, Petersen EP, Sykes J, et al. 2020 AAHA/AAFP feline vaccination guidelines. *J Feline Med Surg* 2020;22(9):813–30. <https://doi.org/10.1177/1098612X20941784>.
- [3] Horzinek MC, Addie D, Belák S, Boucraut-Baralon C, Egberink H, Frymus T, et al. ABCD: update of the 2009 guidelines on prevention and management of feline infectious diseases. *J Feline Med Surg* 2013;15(7):530–9. <https://doi.org/10.1177/1098612X13489208>.
- [4] Hosie MJ, Addie DD, Boucraut-Baralon C, Egberink H, Frymus T, Gruffydd-Jones T, et al. Matrix vaccination guidelines: 2015 ABCD recommendations for indoor/outdoor cats, rescue shelter cats and breeding catteries. *J Feline Med Surg* 2015;17(7):583–7. <https://doi.org/10.1177/1098612X15590732>.
- [5] Gaskell RM, Gettinby G, Graham SJ, Skilton D. Veterinary Products Committee working group report on feline and canine vaccination. *Vet Rec* 2002;150(5):126–34.
- [6] Moore GE, DeSantis-Kerr AC, Guptill LF, Glickman NW, Lewis HB, Glickman LT. Adverse events after vaccine administration in cats: 2,560 cases (2002–2005). *J Am Vet Med Assoc* 2007;231(1):94–100. <https://doi.org/10.2460/javma.231.1.94>.
- [7] McEntee MC, Page RL. Feline vaccine-associated sarcomas. *J Vet Intern Med* 2001;15(3):176–82. <https://doi.org/10.1111/j.1939-1676.2001.tb02308.x>.

- [8] Kirpensteijn J. Feline injection site-associated sarcoma: Is it a reason to critically evaluate our vaccination policies? *Vet Microbiol* 2006;117(1):59–65. <https://doi.org/10.1016/j.vetmic.2006.04.010>.
- [9] Hartmann K, Day MJ, Thiry E, Lloret A, Frymus T, Addie D, et al. Feline injection-site sarcoma: ABCD guidelines on prevention and management. *J Feline Med Surg* 2015;17(7):606–13. <https://doi.org/10.1177/1098612X15588451>.
- [10] Dean RS, Pfeiffer DU, Adams VJ. The incidence of feline injection site sarcomas in the United Kingdom. *BMC Vet Res* 2013;9:17. <https://doi.org/10.1186/1746-6148-9-17>.
- [11] Gobar GM, Kass PH. World Wide Web-based survey of vaccination practices, postvaccinal reactions, and vaccine site-associated sarcomas in cats. *J Am Vet Med Assoc* 2002;220(10):1477–82. <https://doi.org/10.2460/javma.2002.220.1477>.
- [12] Kliczkowska K, Jankowska U, Jagielski D, Czopowicz M, Sapieryński R. Epidemiological and morphological analysis of feline injection site sarcomas. *Pol J Vet Sci* 2015;18(2):313–22. <https://doi.org/10.1515/pjvs-2015-0041>.
- [13] Hendrick MJ, Goldschmidt MH, Shofer FS, Wang YY, Somlyo AP. Postvaccinal sarcomas in the cat: epidemiology and electron probe microanalytical identification of aluminum. *Cancer Res* 1992;52(19):5391–4.
- [14] Macy DW. Current understanding of vaccination site-associated sarcomas in the cat. *J Feline Med Surg* 1999;1(1):15–21. [https://doi.org/10.1016/s1098-612x\(99\)90005-0](https://doi.org/10.1016/s1098-612x(99)90005-0).
- [15] Woodward KN. Origins of injection-site sarcomas in cats: the possible role of chronic inflammation—a review. *ISRN Vet Sci* 2011;2011:. <https://doi.org/10.5402/2011/21098210982>.
- [16] Day MJ, Schoon HA, Magnol JP, Saik J, Devauchelle P, Truyen U, et al. A kinetic study of histopathological changes in the subcutis of cats injected with non-adjuvanted and adjuvanted multi-component vaccines. *Vaccine* 2007;25(20):4073–84. <https://doi.org/10.1016/j.vaccine.2007.02.049>.
- [17] Kass PH, Barnes Jr WG, Spangler WL, Chomel BB, Culbertson MR. Epidemiologic evidence for a causal relation between vaccination and fibrosarcoma tumorigenesis in cats. *J Am Vet Med Assoc* 1993;203(3):396–405. Erratum in: *J Am Vet Med Assoc* 1993;203(7):1046.
- [18] Srivastav A, Kass PH, McGill LD, Farver TB, Kent MS. Comparative vaccine-specific and other injectable-specific risks of injection-site sarcomas in cats. *J Am Vet Med Assoc* 2012;241(5):595–602. <https://doi.org/10.2460/javma.241.5.595>.
- [19] Graf R, Grüntzig K, Boo G, Hässig M, Axhausen KW, Fabrikant S, et al. Swiss feline cancer registry 1965–2008: the influence of sex, breed and age on tumour types and tumour locations. *J Comp Pathol* 2016;154(2–3):195–210. <https://doi.org/10.1016/j.jcpa.2016.01.008>.
- [20] Graf R, Guscetti F, Welle M, Meier D, Pospischil A. Feline injection site sarcomas: data from Switzerland 2009–2014. *J Comp Pathol* 2018;163:1–5. <https://doi.org/10.1016/j.jcpa.2018.06.008>.
- [21] Kass PH, Spangler WL, Hendrick MJ, McGill LD, Esplin DG, Lester S, et al. Multicenter case-control study of risk factors associated with development of vaccine-associated sarcomas in cats. *J Am Vet Med Assoc* 2003;223(9):1283–92. <https://doi.org/10.2460/javma.2003.223.1283>.
- [22] Wilcock B, Wilcock A, Bottoms K. Feline postvaccinal sarcoma: 20 years later. *Can Vet J* 2012;53(4):430–4.
- [23] ABCD. Feline injection-site sarcoma. Guidelines general. Updated November 2021, last review November 2022. <http://www.abcdcatsvets.org/feline-injection-site-sarcoma-2/> [accessed 11 December 2022].
- [24] Jas D, Frances-Duvert V, Brunet S, Oberli F, Guigal PM, Poulet H. Evaluation of safety and immunogenicity of feline vaccines with reduced volume. *Vaccine* 2021;39(7):1051–7. <https://doi.org/10.1016/j.vaccine.2021.01.026>.
- [25] Bernau M, Kremer PV, Kreuzer LS, Emrich D, Pappenberger E, Cussler K, et al. Assessment of local reaction to vaccines in live piglets with magnetic resonance imaging compared to histopathology. *ALTEX* 2016;33(1):29–36. <https://doi.org/10.14573/altex.1507211>.
- [26] Bernau M, Kremer-Rücker PV, Kreuzer LS, Schwanitz S, Cussler K, Hoffmann A, et al. Magnetic resonance imaging to detect local tissue reactions after vaccination in sheep in vivo. *Vet Rec Open* 2017;4(1):. <https://doi.org/10.1136/vetreco-2016-000200e000200>.
- [27] Bernau M, Liesner BG, Schwanitz S, Kraus AS, Falkenau A, Leipig-Rudolph M, et al. Vaccine safety testing using magnetic resonance imaging in suckling pigs. *Vaccine* 2018;36(13):1789–95. <https://doi.org/10.1016/j.vaccine.2018.02.025>.
- [28] Rodríguez-Largo A, Castells E, de Miguel R, Gómez Á, Ruiz H, Pérez M, et al. Detection of aluminium hydroxide-induced granulomas in sheep by computed tomography: a feasible approach for small ruminant lentiviruses diagnosis and research. *Vet Med Sci* 2021;7(5):1757–61. <https://doi.org/10.1002/vms3.572>.
- [29] Travetti O, di Giancamillo M, Stefanello D, Ferrari R, Giudice C, Grieco V, et al. Computed tomography characteristics of fibrosarcoma – a histological subtype of feline injection-site sarcoma. *J Feline Med Surg* 2013;15(6):488–93. <https://doi.org/10.1177/1098612x12472174>.
- [30] Longo M, Zani DD, Ferrari R, Bassi J, Andreis ME, Stefanello D, et al. Dynamic tomographic studies of interscapular feline injection-site sarcoma: essential or useless practice? *J Feline Med Surg* 2018;20(6):502–8. <https://doi.org/10.1177/1098612x17717176>.
- [31] Ferrari R, Di Giancamillo M, Stefanello D, Giudice C, Grieco V, Longo M, et al. Clinical and computed tomography tumour dimension assessments for planning wide excision of injection site sarcomas in cats: how strong is the agreement? *Vet Comp Oncol* 2017;15(2):374–82. <https://doi.org/10.1111/vco.12173>.
- [32] Rojas A, Dvir E, Baneth G. Insights on *Spirocerca lupi*, the carcinogenic dog nematode. *Trends Parasitol* 2020;36(1):52–63. <https://doi.org/10.1016/j.pt.2019.10.004>.
- [33] Madewell BR, Griffey SM, McEntee MC, Leppert VJ, Munn RJ. Feline vaccine-associated fibrosarcoma: an ultrastructural study of 20 tumors (1996–1999). *Vet Pathol* 2001;38(2):196–202. <https://doi.org/10.1354/vp.38-2-196>.
- [34] Deim Z, Palmal N, Cserni G. Feline vaccine-associated fibrosarcoma induced by aluminium compound in two cats: short communication. *Acta Vet Hung* 2008;56(1):111–6. <https://doi.org/10.1556/avet.56.2008.1.11>.
- [35] Hsueh CS, Wu CH, Shih CH, Yeh JL, Jeng CR, Pang VF, et al. Role of nuclear factor-kappa B in feline injection site sarcoma. *BMC Vet Res* 2019;15(1):365. <https://doi.org/10.1186/s12917-019-2100-9>.
- [36] Shih CH, Chang YC, Lai YC, Chiou HY. Investigating the role of signal transducer and activator of transcription 3 in feline injection site sarcoma. *BMC Vet Res* 2022;18(1):276. <https://doi.org/10.1186/s12917-022-03352-y>.